

NEUROLOGICAL EXAMINATION OF AN INFANT, DOES IT DIFFER....?! DR AMR HASAN AL HASANY

By

Amr Hasan M.D,

Associate Professor of Neurology
Cairo University

HISTORY TAKING

HISTORY TAKING

- Neurological examination in pediatrics varies according to age e.g. : the approach to neonates will vary from that of children.
- Observation is key to diagnosis since physical signs are usually less obvious than in adults.
- Talk to the parents .

HISTORY TAKING

- A child older than 3 to 5 years might provide information that not only is valuable, but also may be more reliable than that related by his or her parents.
- Do not ask leading questions.
- The physician also must be responsive to the youngster's mood and cease taking a history as soon as fatigue or restlessness becomes evident.
- In a younger child or one with a limited attention span, the salient points of the history are best secured at the onset of the evaluation.

HISTORY TAKING

- Allow older children play as you observe.
- This may require that you have some toys.
- Communicate with the children.

HISTORY TAKING

- A review of the perinatal events is always in order.
- Feeding history.
- A history of abnormal sleeping habits.
- Major childhood illnesses.
- Immunizations.
- Injuries.
- The family history.

EXAMINATION

GENERAL PHYSICAL EXAMINATION

- The toddler is more difficult to examine. The toddler is best approached by seating the child in the mother's or father's lap and talking to the child.
- Because toddlers are fearful of strangers, the physician must first observe the youngster and defer touching him or her until some degree of rapport has been established.

GENERAL PHYSICAL EXAMINATION

- Offering a small, interesting toy may bridge the gap.
- Once frightened, most toddlers are difficult to reassure and are lost for the remainder of the examination.

GENERAL PHYSICAL EXAMINATION

- The child's height, weight, blood pressure, and head circumference must always be measured and recorded.
- The youngster should be undressed by the parents, with the physician absent.
- The physician should note the general appearance of the child.
- Note facial configuration,presence of any dysmorphic feature & Cutaneous lesions.

GENERAL PHYSICAL EXAMINATION

- The condition of the teeth provides information about antenatal defects or kernicterus.
- The location of the hair whorl and the appearance of the palmar creases should always be noted.

GENERAL PHYSICAL EXAMINATION

- The quality of the scalp hair, eyebrows, and nails also should be taken into account.
- It is important to inspect the midline of the neck, back, and pilonidal area for any defects, particularly for small dimples that might indicate the presence of a dermoid sinus tract.

GENERAL PHYSICAL EXAMINATION

- Examination of chest, heart, and abdomen and palpation of the femoral pulses should always be part of the general physical examination.
- Finally, the presence of an unusual body odor may offer a clue to a metabolic disorder.

- ▣ Clinical examination video\Group 1\02
General aspects.mpg

DR AMR HASAN AL HASANY

- ▣ Clinical examination video\Group 1\03
Psychomotor development.mpg

DR AMR HASAN AL HASANY

Neurologic examination of the infant

The neurologic examination of an infant younger than 1 year of age can be divided into three parts:

1. Evaluation of posture and tone
2. Evaluation of primitive reflexes
3. Age invariable tests.

Neurologic examination of the infant

The neurologic examination of an infant younger than 1 year of age can be divided into three parts:

1. Evaluation of posture and tone
2. Evaluation of primitive reflexes
3. Age invariable tests.

Neurologic examination of the infant

1. Evaluation of posture and tone

Evaluation of posture and muscle tone is a fundamental part of the neurologic examination of infants. It involves examination of :

- A. Resting Posture
- B. Passive Tone
- C. Active Tone

Neurologic examination of the infant

1. Evaluation of posture and tone:

A . R e s t i n g P o s t u r e :

Posture is appreciated by inspecting the undressed

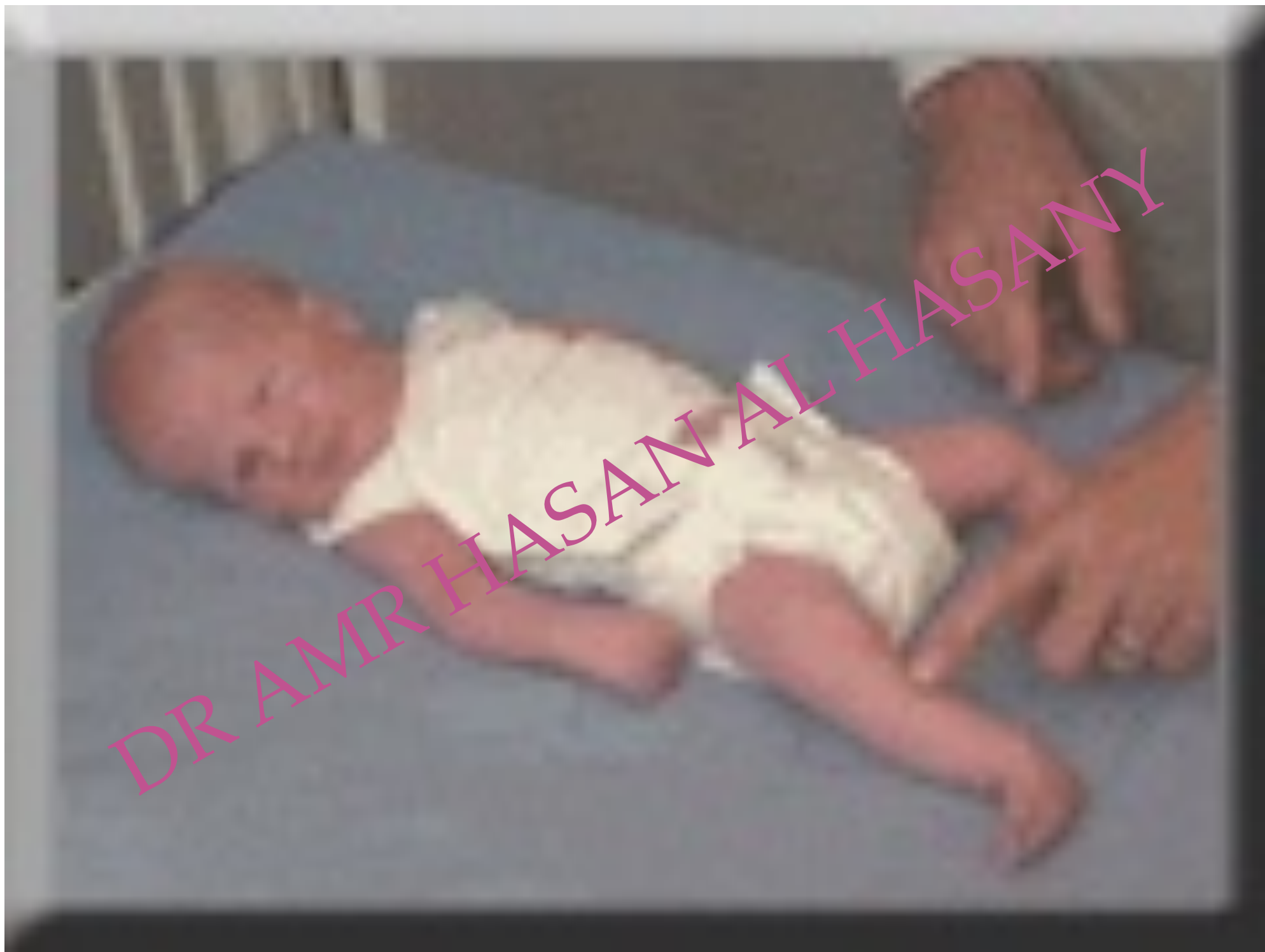- ▣ During the first few months of life, normal hypertonia of the flexors of the elbows, hips, and knees occurs .
- ▣ The hypertonia decreases markedly during the third month of life, first in the upper extremities and later in the lower extremities.

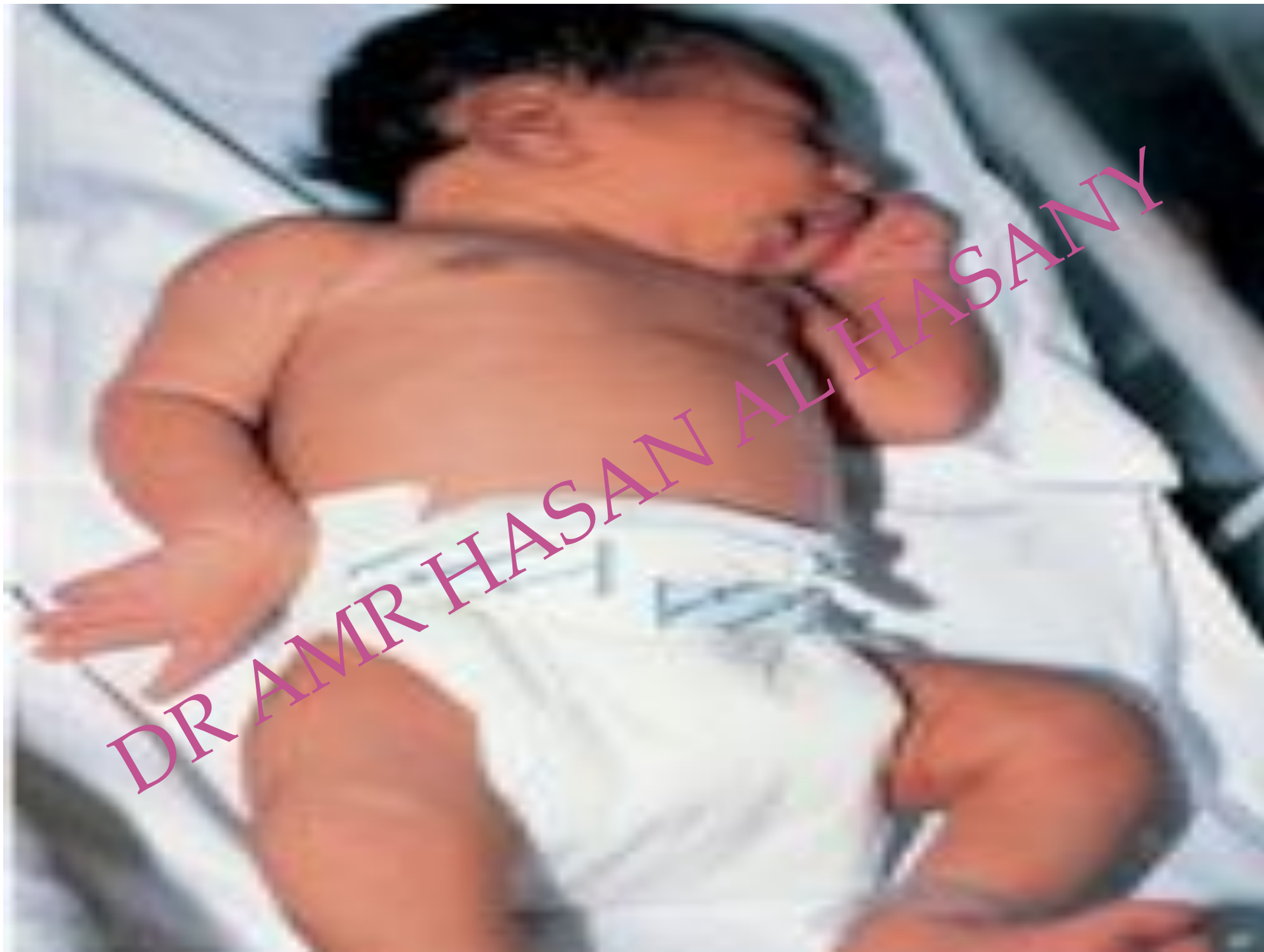Neurologic examination of the infant

1. Evaluation of posture and tone:

A . R e s t i n g P o s t u r e :

- ▣ At the same time, tone in neck and trunk increases.
- ▣ Between 8 and 12 months of age, a further decrease occurs in the flexor tone of the extremities together with increased extensor tone.



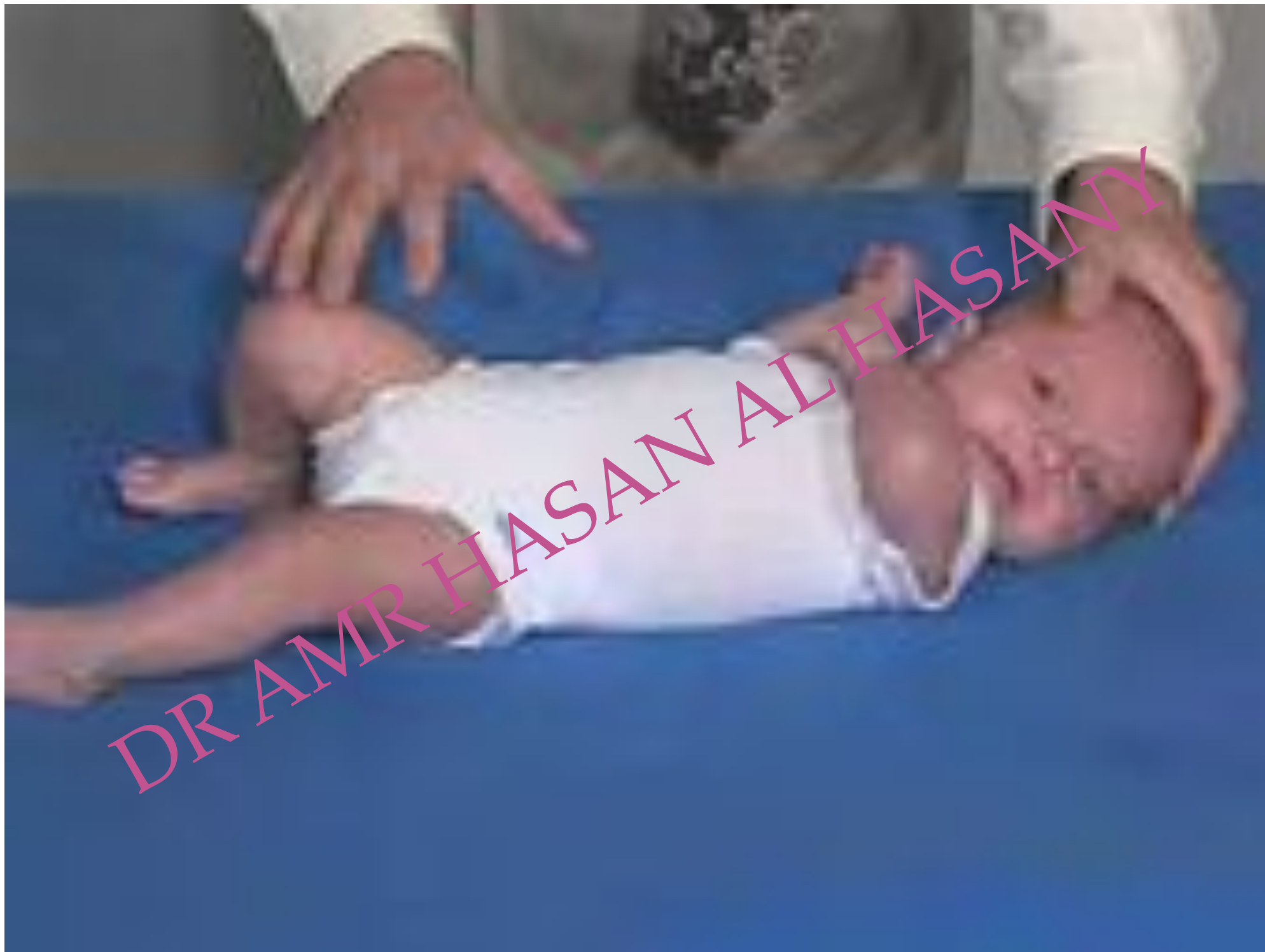

Neurologic examination of the infant

1. Evaluation of posture and tone

B. Passive tone

- ▣ Is accomplished by determining the resistance to passive movements of the various joints with the infant awake and not crying.
- ▣ Because limb tone is influenced by tonic neck reflexes, it is important to keep the child's head straight during this part of the examination.



Neurologic examination of the infant

1. Evaluation of posture and tone

B. Passive tone

- ▣ Passive flapping of the hands and the feet provides a simple means of ascertaining muscle tone.
- ▣ In the upper extremity, the scarf sign is a valuable maneuver.
- ▣ In the lower extremity, the fall-away response serves a similar purpose.



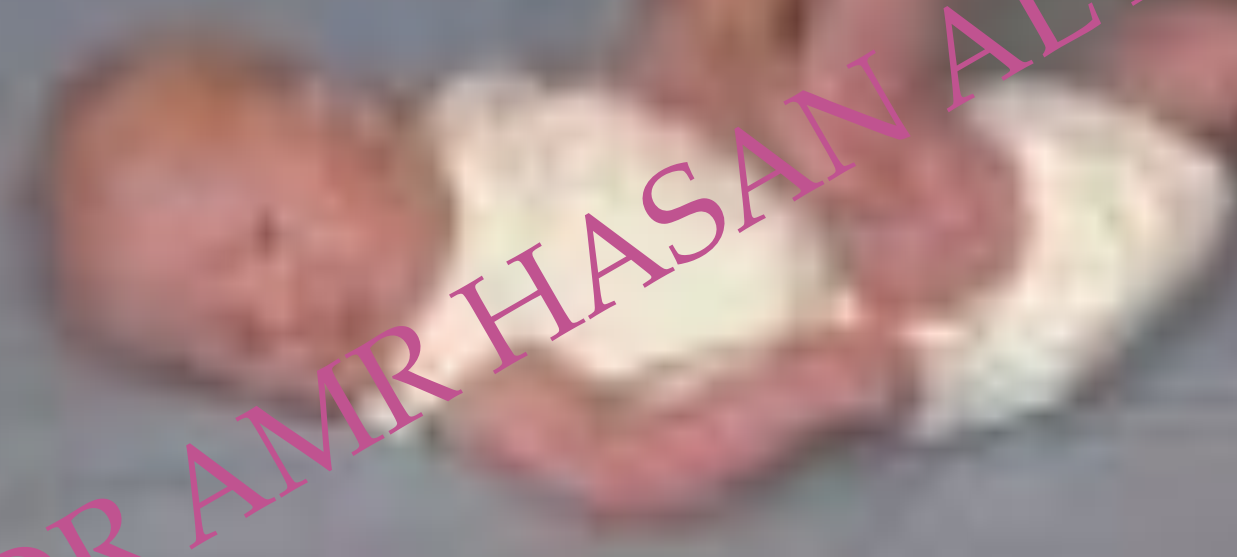DR AMR HASAN AL HASANY



DR AMR HASAN ALHASANY



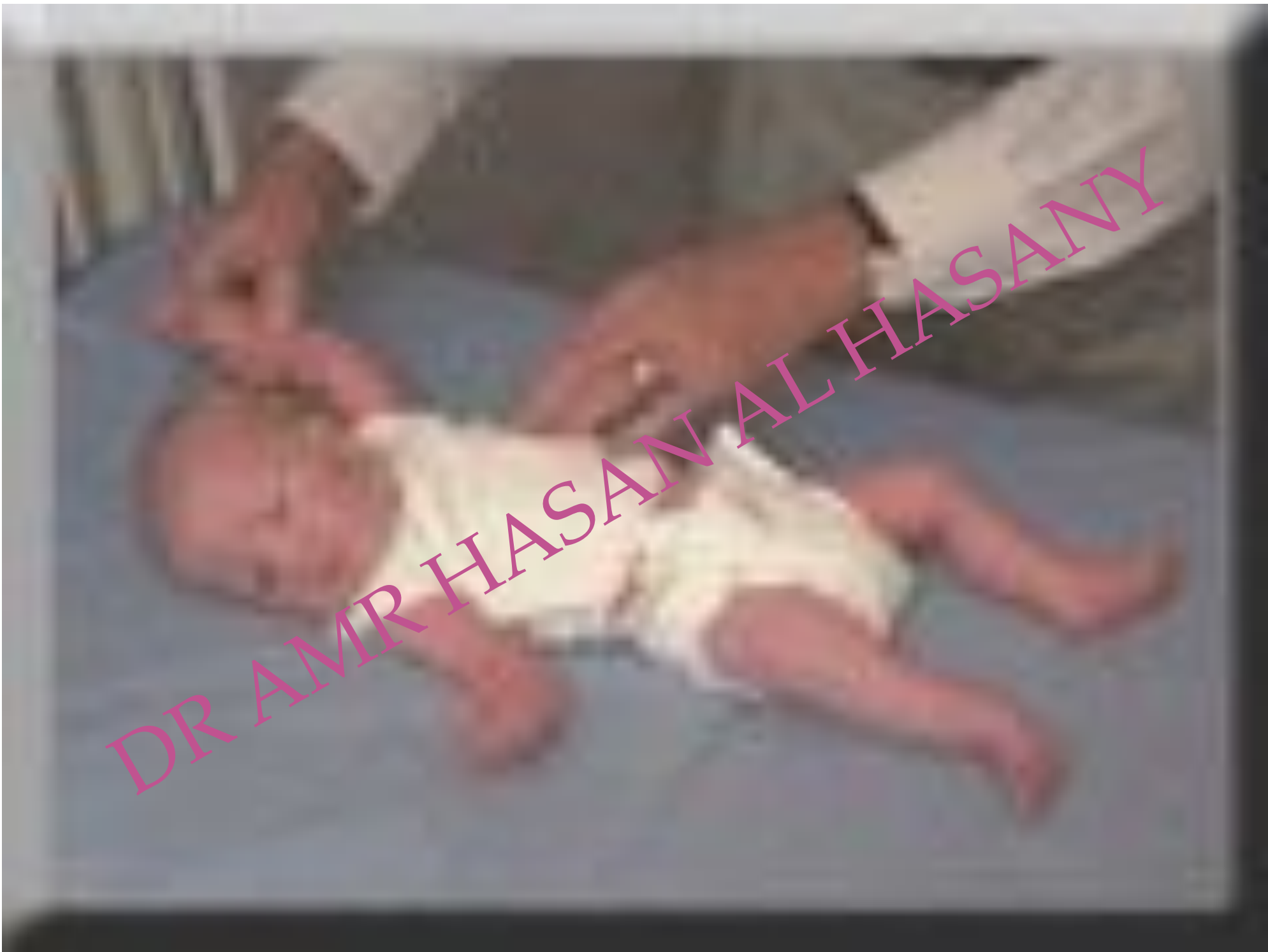DR AMR HASAN ALHASANY



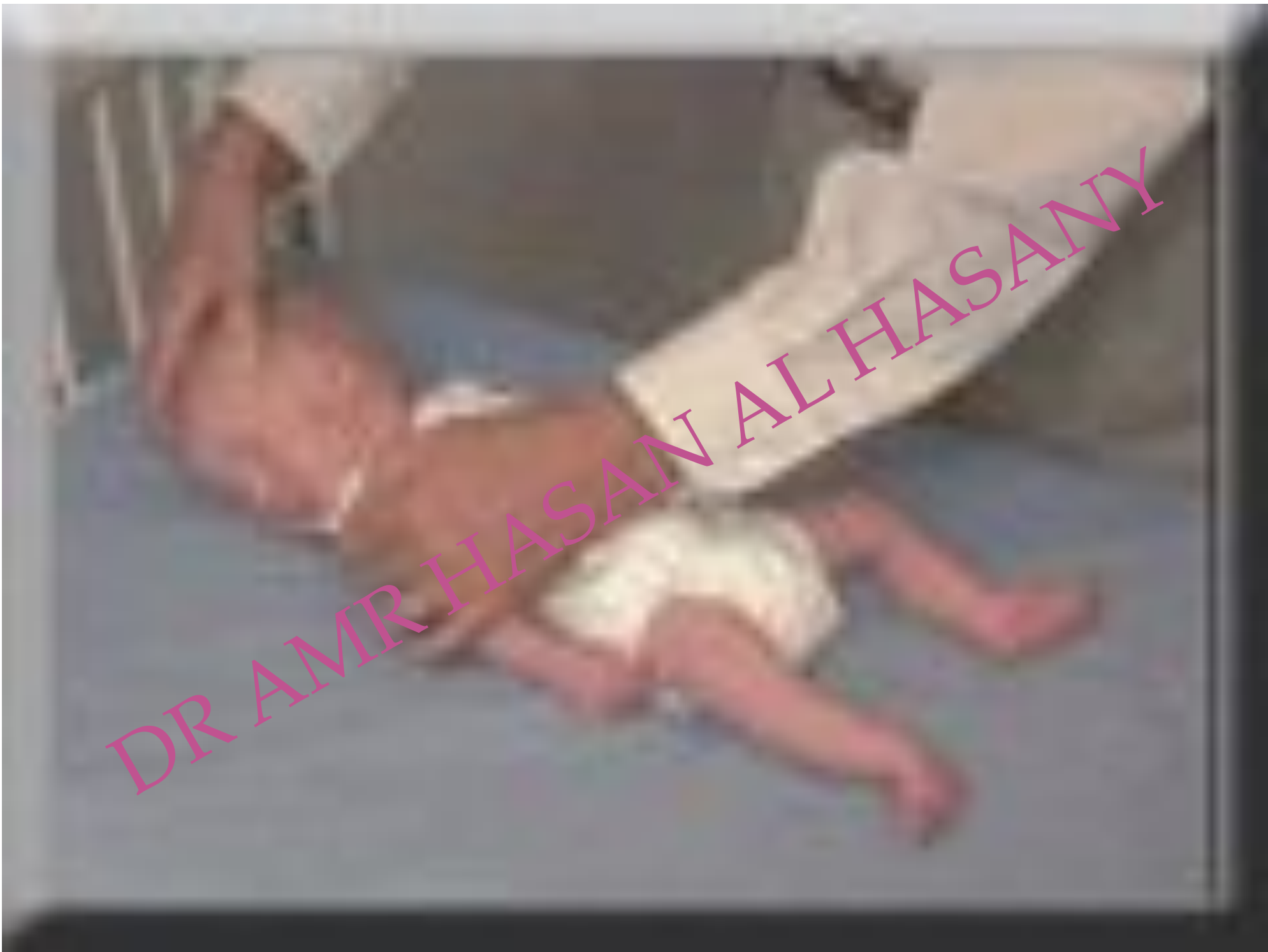DR AMR HASAN ALHASANY



DR AMR HASAN ALHASANY



DR AMR HASAN ALHASANY



Neurologic examination of the infant

1. Evaluation of posture and tone:

C . A c t i v e t o n e :

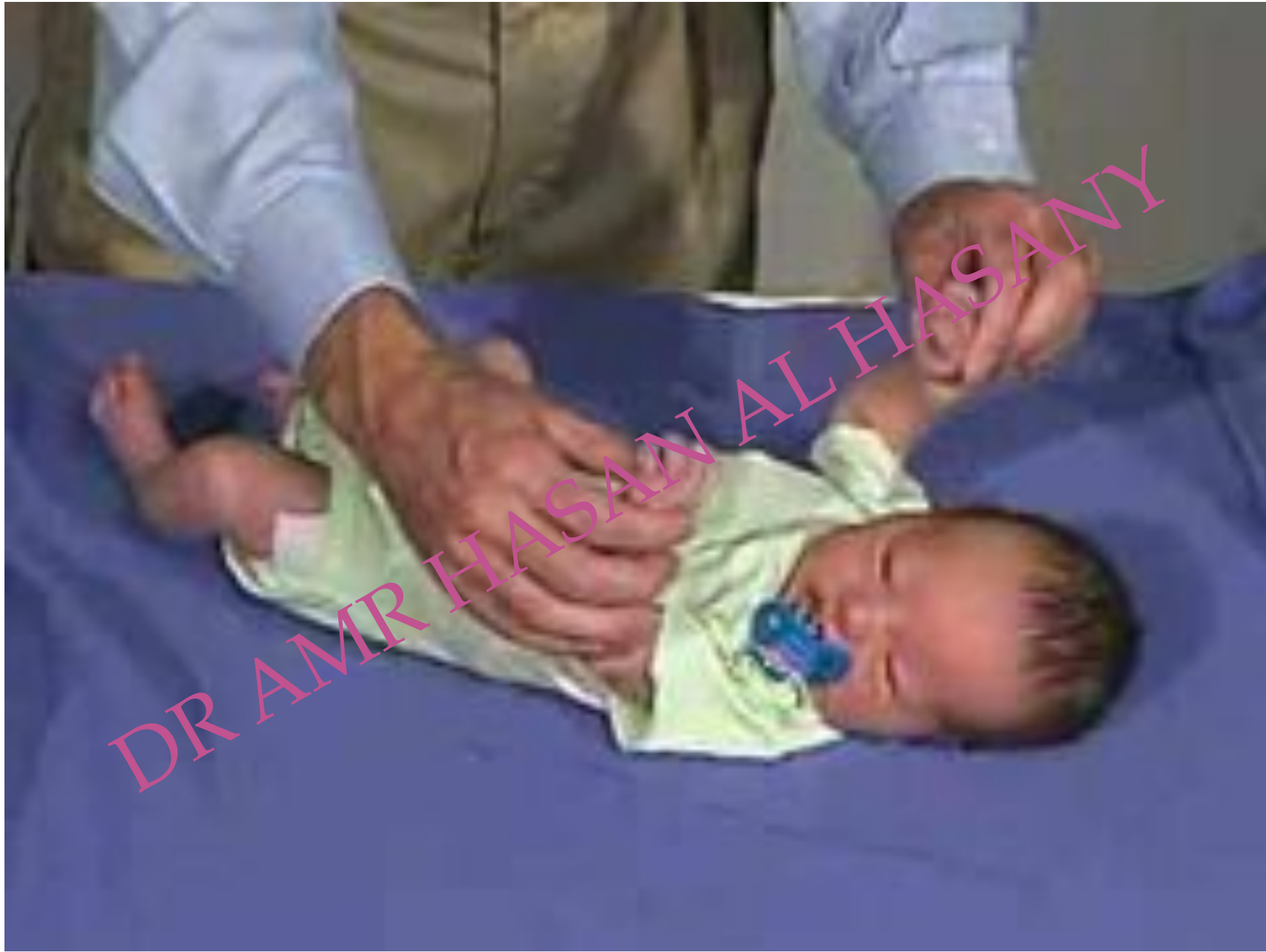- ▣ The **traction response** is an excellent means of a s c e r t a i n i n g **a c t i v e t o n e**
- ▣ The examiner, who should be sitting down and facing the child, places his or her thumbs in the infant's palms and fingers around the wrists and gently pulls the infant from the supine p o s i t i o n .

Neurologic examination of the infant

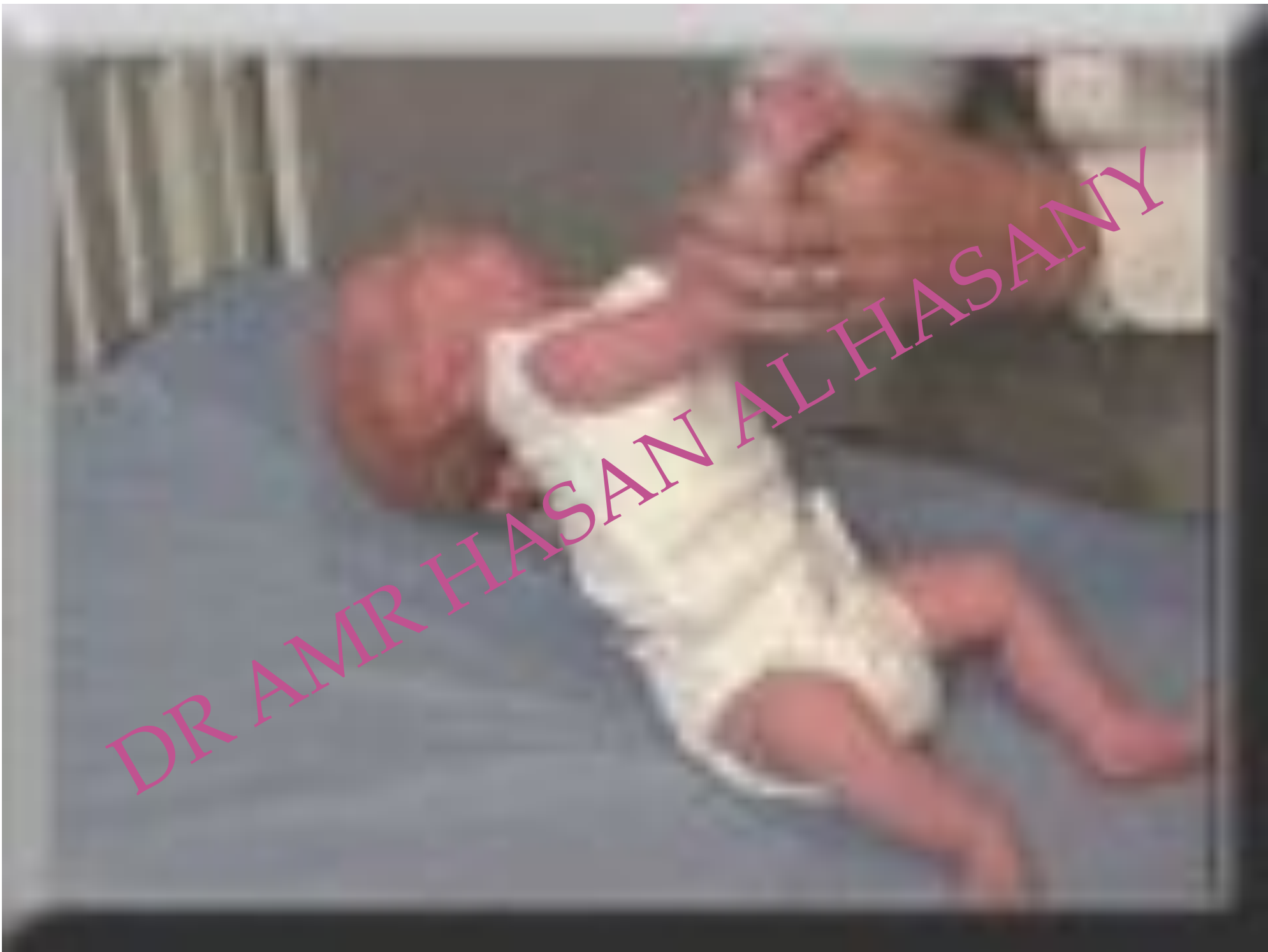1. Evaluation of posture and tone:

C . A c t i v e t o n e :

- ▣ In the healthy infant younger than 3 months of age, the palmar grasp reflex becomes operative, the elbows tend to flex, and the flexor muscles of the neck are stimulated to raise the head so that even in the full-term neonate the extensor and flexor tone are balanced and the head is maintained briefly in the axis of the trunk.



DR AMR HASAN ALHASANY



DR AMR HASAN ALHASANY



- ▣ [exam video\05 Func int-MS-Tone.mpg](#)

DR AMR HASAN AL HASANY

Neurologic examination of the infant

The neurologic examination of an infant younger than 1 year of age can be divided into three parts:

1. Evaluation of posture and tone
2. Evaluation of primitive reflexes
3. Age invariable tests.

Neurologic examination of the infant

The neurologic examination of an infant younger than 1 year of age can be divided into three parts:

1. Evaluation of posture and tone
2. Evaluation of primitive reflexes
3. Age invariable tests.

Neurologic examination of the infant

2. Evaluation of primitive reflexes:

- ▣ The evaluation of primitive reflexes is an integral part of the neurologic examination of the infant.
- ▣ This disappearance should not be construed as meaning that they are actually lost, for a reflex once acquired in the course of development is retained permanently.

Neurologic examination of the infant

2. Evaluation of primitive reflexes:

- ▣ Rather, these reflexes, which develop during intrauterine life, are gradually suppressed as the higher cortical centers become functional.

Neurologic examination of the infant

2 . E v a l u a t i o n o f p r i m i t i v e r e f l e x e s :

A. Segmental Medullary Reflexes: A number of segmental medullary reflexes become functional during the last trimester of gestation. They include

(a) r e s p i r a t o r y a c t i v i t y .

(b) c a r d i o v a s c u l a r r e f l e x e s .

(c) coughing reflex mediated by the vagus nerve.

(d) sneezing reflex evoked by afferent fibers of the trigeminal nerve.

(e) swallowing reflex mediated by the trigeminal and glossopharyngeal nerves.

(f) s u c k i n g r e f l e x .

Neurologic examination of the infant

2. Evaluation of primitive reflexes:

B. Flexion Reflex:

- ▣ This response is elicited by the unpleasant stimulation of the skin of the lower extremity, most consistently the dorsum of the foot, and consists of dorsiflexion of the great toe and flexion of the ankle, knee, and hip.

Neurologic examination of the infant

2. Evaluation of primitive reflexes:

B. Flexion Reflex

- ▣ This reflex has been elicited in immature fetuses and can persist as a fragment, the extensor plantar response, for the first 2 years of life. It is seen also in infants whose higher cortical centers have been profoundly damaged.

Neurologic examination of the infant

2. Evaluation of primitive reflexes:

C. Moro Reflex

The Moro reflex is best elicited by a sudden dropping of the baby's head in relation to its trunk. Moro, however, elicited this reflex by hitting the infant's pillow with both hands.

Neurologic examination of the infant

2. Evaluation of primitive reflexes:

C. Moro Reflex

- ▣ The infant opens the hands, extends and abducts the upper extremities, and then draws them together. The reflex first appears between 28 and 32 weeks' gestation and is present in all newborns.
- ▣ It fades out between 3 to 5 months of age.



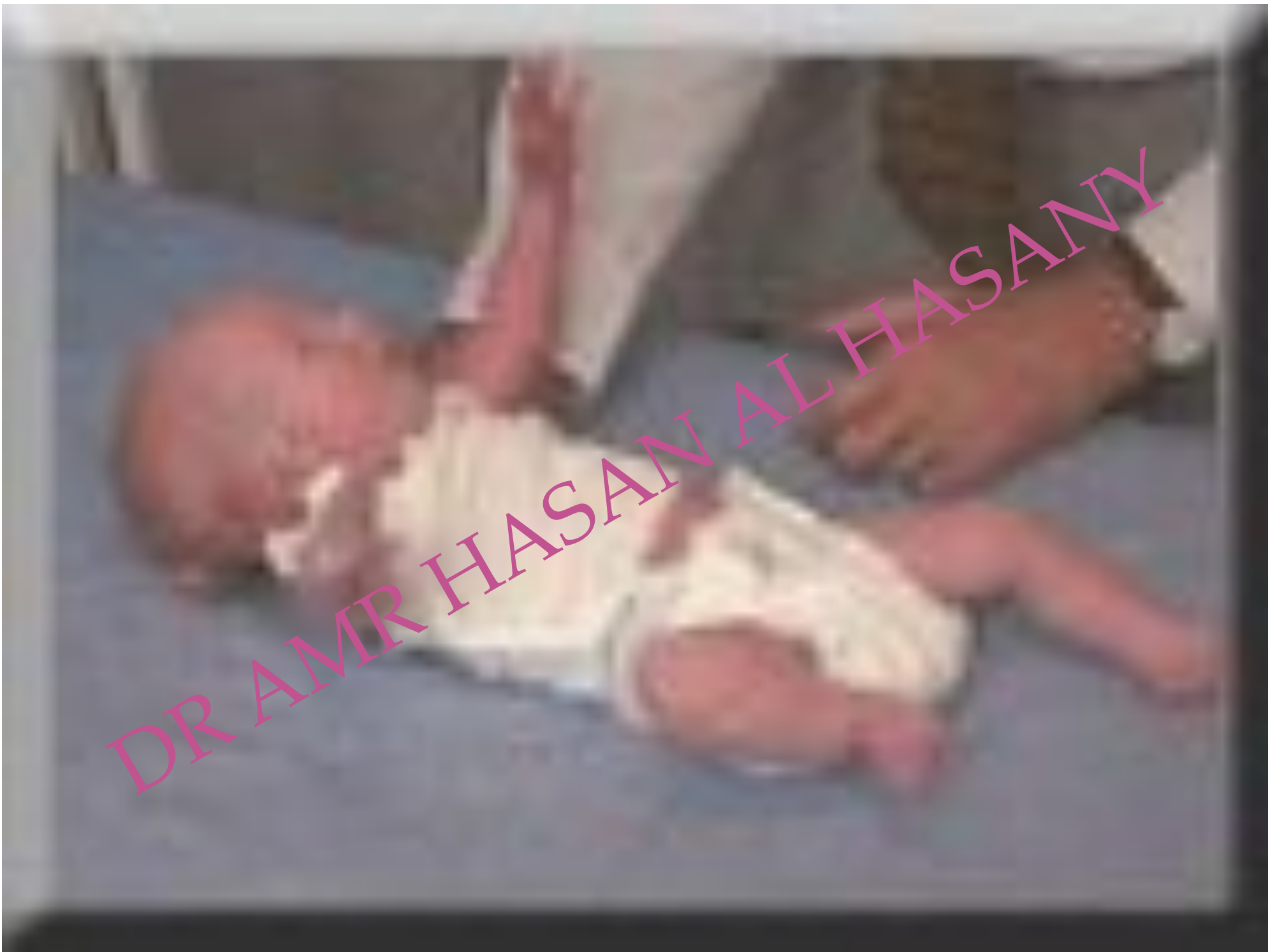Neurologic examination of the infant

2. Evaluation of primitive reflexes:

C. Moro Reflex

Its persistence beyond 6 months of age or its absence or diminution during the first few weeks of life indicates neurologic dysfunction.

DR AMR HASAN ALHASANY



The Moro reflex

DR AMR HASAN ALHASANY

Neurologic examination of the infant

2. Evaluation of primitive reflexes:

D. Tonic Neck Response

The tonic neck response is obtained by rotating the infant's head to the side while maintaining the chest in a flat position.

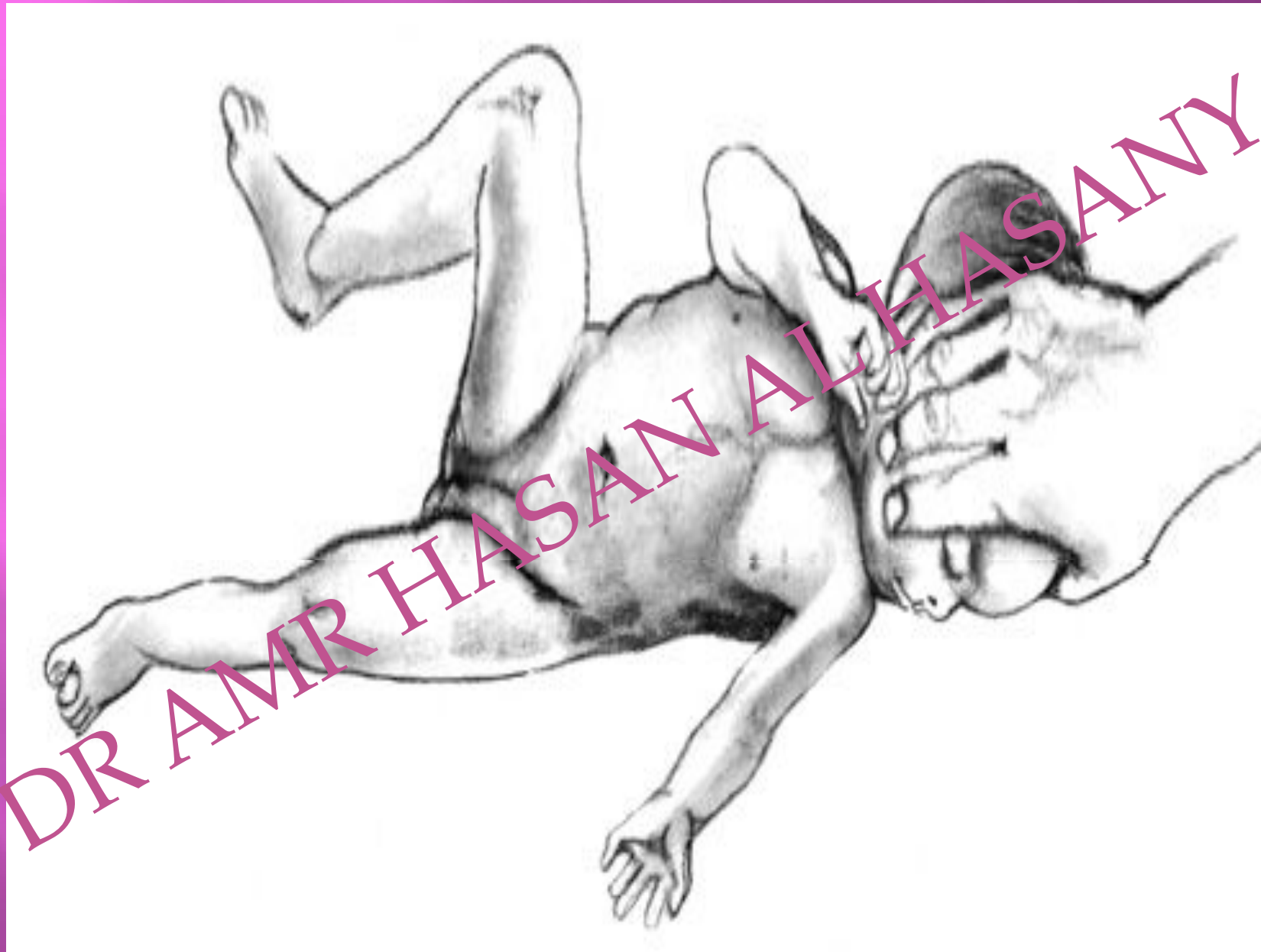A positive response is extension of the arm and leg on the side toward which the face is rotated and flexion of the limbs on the opposite side.

Neurologic examination of the infant

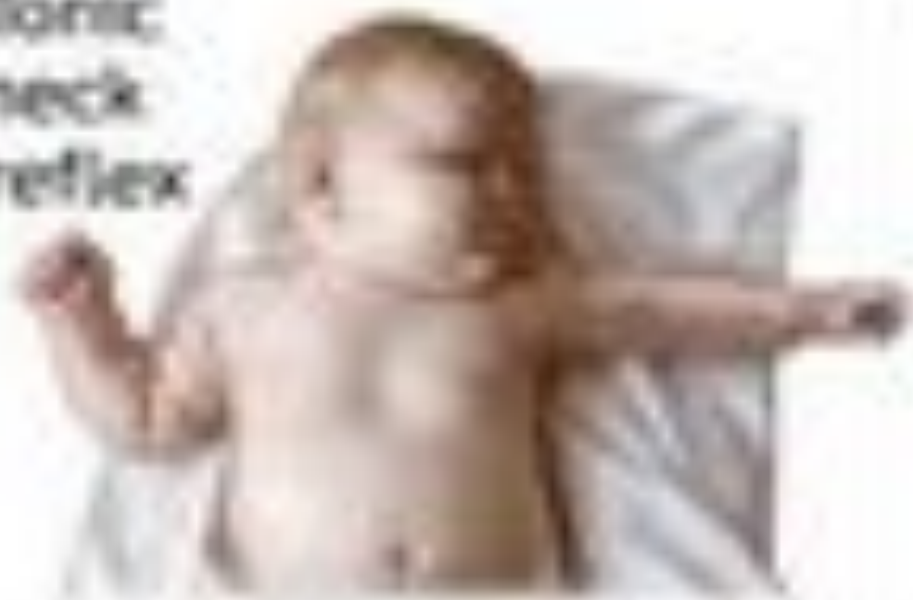2. Evaluation of primitive reflexes:

D. Tonic Neck Response

Inconstant tonic neck responses can be elicited for as long as 6 to 7 months of age and can even be momentarily present during sleep in the healthy 2- to 3-year-old child .



Tonic
neck
reflex



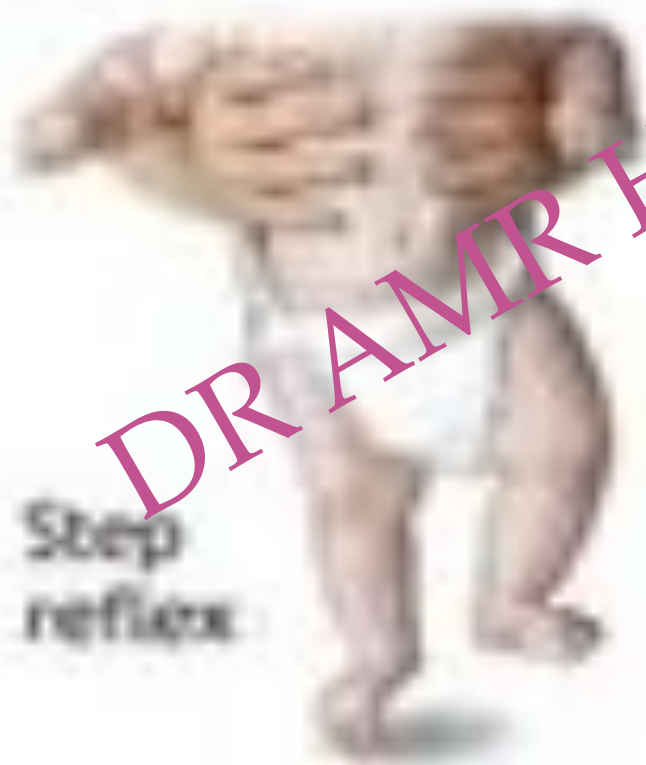Grasp
reflex



Crawl reflex



Step
reflex






Neurologic examination of the infant

2. Evaluation of primitive reflexes:

E.Righting Reflex

- ▣ With the infant in the supine position, the examiner turns the head to one side. The healthy infant rotates the shoulder in the same direction, followed by the trunk, and finally the pelvis.
- ▣ An obligate neck-righting reflex in which the shoulders, trunk, and pelvis rotate simultaneously and in which the infant can be rolled over and over like a log is always a normal finding.



Neurologic examination of the infant

2. Evaluation of primitive reflexes:

F. Palmar and Plantar Grasp Reflexes

- ▣ The palmar and plantar grasp reflexes are elicited by pressure on the palm or sole.
- ▣ Generally, the plantar grasp reflex is weaker than the palmar reflex.

Neurologic examination of the infant

2. Evaluation of primitive reflexes:

F. Palmar and Plantar Grasp Reflexes:

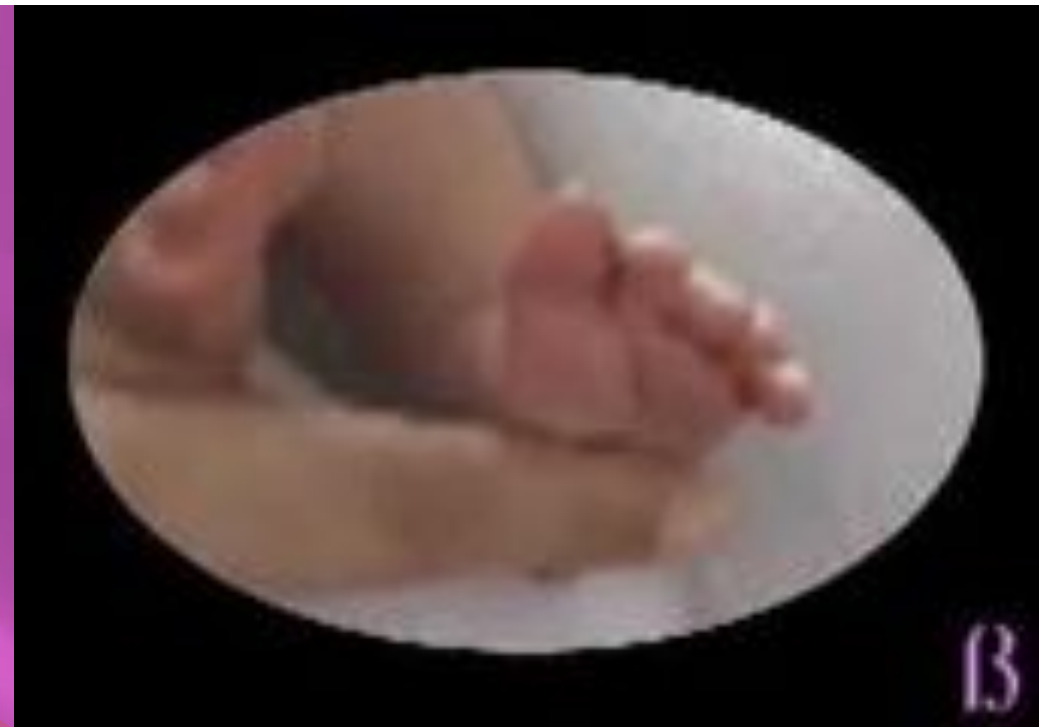- ▣ The palmar grasp reflex appears at 28 weeks' gestation, is well established by 32 weeks, and becomes weak and inconsistent between 2 and 3 months of age, when it is covered up by voluntary activity.

Neurologic examination of the infant

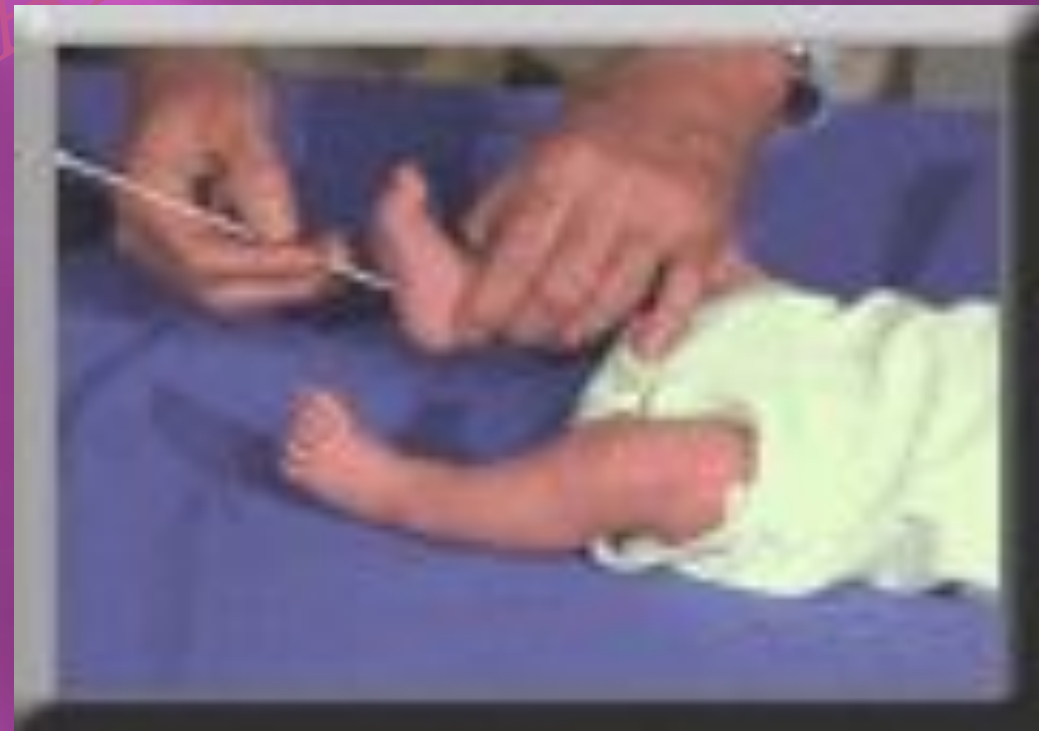2. Evaluation of primitive reflexes:

F. Palmar and Plantar Grasp Reflexes:

- ▣ Absence of the reflex before 2 or 3 months of age, persistence beyond that age, or a consistent asymmetry is abnormal.
- ▣ The reappearance of the grasp reflex in frontal lobe lesions reflects the unopposed parietal lobe activity.



β



DR AMR HASAN

Neurologic examination of the infant

2. Evaluation of primitive reflexes:

G.Vertical Suspension

- ▣ The examiner suspends the child with his or her hand under its axillae and notes the position of the lower extremities.
- ▣ Marked extension or scissoring is an indication of spasticity.



Neurologic examination of the infant

2. Evaluation of primitive reflexes:

H . L a n d a u R e f l e x

- ▣ To elicit the Landau response, the examiner lifts the infant with one hand under the trunk, face downward.
- ▣ Normally, a reflex extension of the vertebral column occurs, causing the newborn infant to lift the head to slightly below the horizontal, which results in a slightly convex upward curvature of the spine. With hypotonia, the infant's body tends to collapse into an inverted U shape.



Neurologic examination of the infant

2. Evaluation of primitive reflexes:

H . L a n d a u R e f l e x

- ▣ With hypotonia, the infant's body tends to collapse into an inverted U shape.

DR AMR HASAN ALHASANY



Neurologic examination of the infant

2. Evaluation of primitive reflexes:

I. Buttress Response

- ▣ To elicit the buttress response, the examiner places the infant in the sitting position and displaces the center of gravity with a gentle push on one shoulder.

Neurologic examination of the infant

2. Evaluation of primitive reflexes:

I. Butress Response

- ▣ The infant extends the contralateral arm and spreads the fingers.
- ▣ The reflex normally appears at approximately 5 months of age. Delay in its appearance and asymmetries are significant.

Neurologic examination of the infant

2. Evaluation of primitive reflexes:

I.Parachute Response

- ▣ The parachute reflex is tested with the child suspended horizontally about the waist, face down.
- ▣ The infant is then suddenly projected toward the floor, with a consequent extension of the arms and spreading of the fingers.

Neurologic examination of the infant

2. Evaluation of primitive reflexes:

I.Parachute Response:

- ▣ Between 4 and 9 months of age, this reflex depends on visual and vestibular sensory input and is proportional to the size of the optic stimulus pattern on the floor.




Parachute Reflex

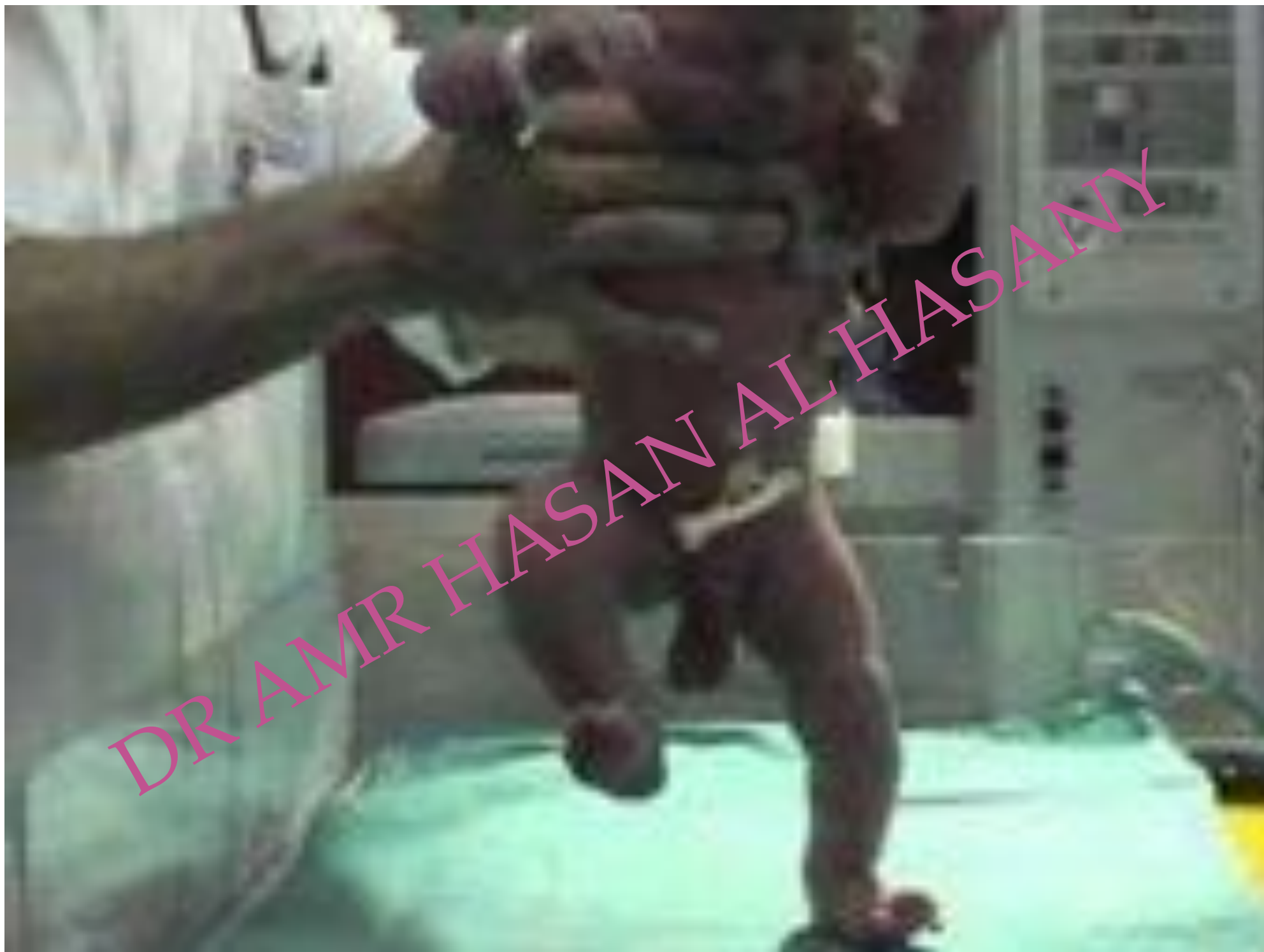Neurologic examination of the infant

2. Evaluation of primitive reflexes:

K. Reflex Placing and Stepping Responses

- ▣ Reflex placing is elicited by stimulating the dorsum of the foot against the edge of the examining table.
- ▣ Reflex stepping, which is at least partly a function of the flexion response, is present in the healthy newborn when the infant is supported in the standing position; it disappears in the fourth or fifth month of life.

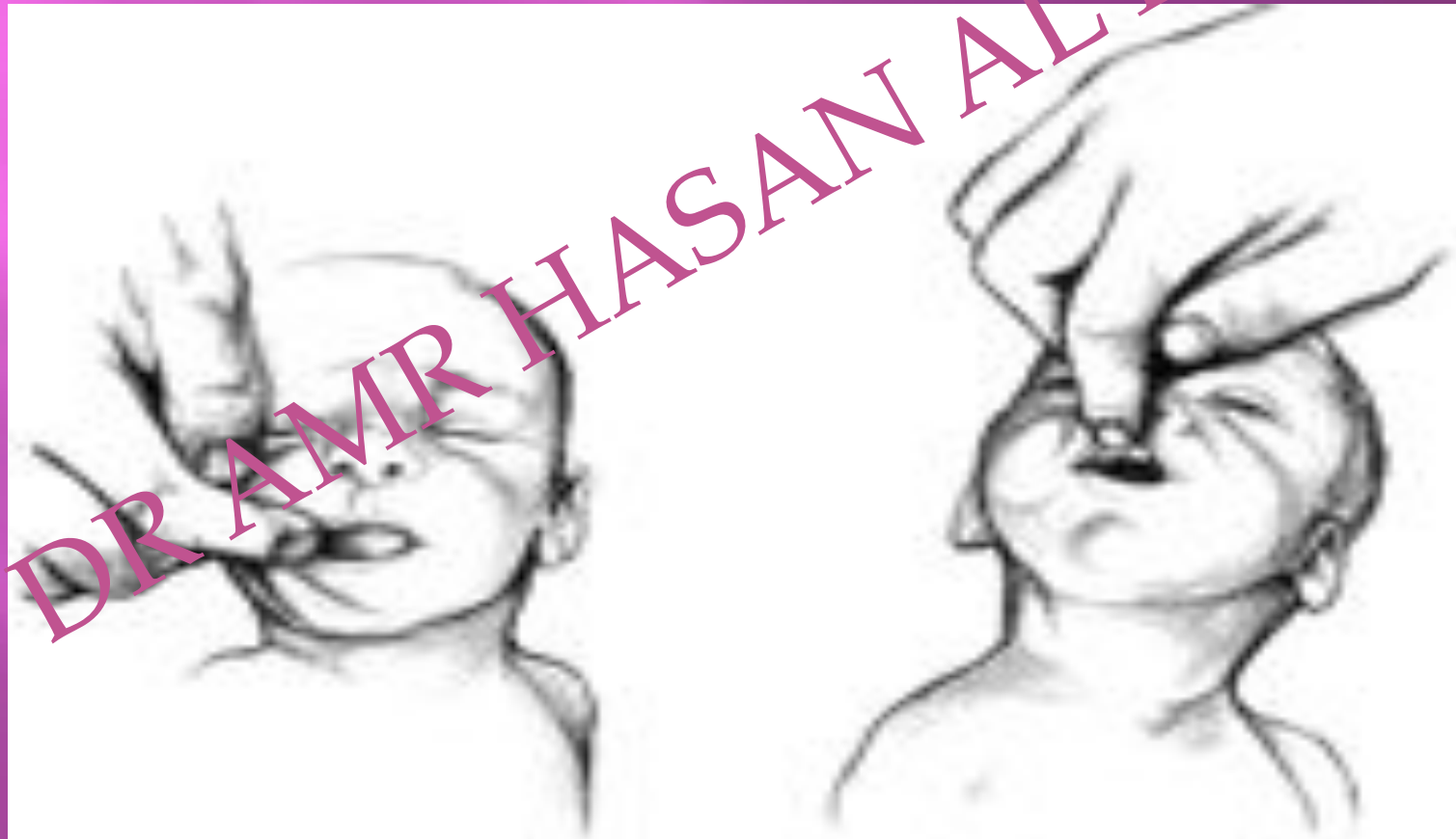



Neurologic examination of the infant

2. Evaluation of primitive reflexes:

L. Reflex Suck, Root



- ▣ [exam video\06 Func_int-DevRfx.mpg](#)

DR AMR HASAN AL HASANY

Neurologic examination of the infant

The neurologic examination of an infant younger than 1 year of age can be divided into three parts:

1. Evaluation of posture and tone
2. Evaluation of primitive reflexes
3. Age invariable tests.

Neurologic examination of the infant

The neurologic examination of an infant younger than 1 year of age can be divided into three parts:

1. Evaluation of posture and tone
2. Evaluation of primitive reflexes
3. Age invariable tests.

Neurologic examination of the infant

3.Age-Invariable Tests

The last part of the neurologic examination involves tests similar to those performed in older children or adults, such as the funduscopic examination and the deep tendon reflexes.

Neurologic examination of the infant

- In addition to the standard instruments used in neurologic examination, the following have been found useful:
 - a tennis ball
 - few small toys
 - a bell
 - some object that attracts the child's attention (e.g., a pin wheel).

Neurologic examination of the infant

- In most intellectually healthy school-aged children, the general physical and neurologic examinations can be performed in the same manner as for adults
- Except that fundus examination, corneal and gag reflexes and sensory testing, should be postponed until the end.

Neurologic examination of the infant

O l f a c t o r y N e r v e

Olfactory sensation as transmitted by the olfactory nerve is not functional in the newborn, but is present by 5 to 7 months of age.

Neurologic examination of the infant

O p t i c N e r v e

• F u n d u s e x a m i n a t i o n

• V i s u a l a c q u i t y

• V i s u a l f i e l d

Neurologic examination of the infant

O p t i c N e r v e

- In infants, the optic disc is normally pale and gray, an appearance similar to optic atrophy in later life.

- Premature and newborn infants have incompletely developed uveal pigment, resulting in a pale appearance of the fundus and a clear view of the choroidal blood vessels.

Neurologic examination of the infant

O p t i c N e r v e

•Retinal hemorrhages are seen in one-third of vaginally delivered newborns.

•They are usually small and multiple, and their presence does not necessarily indicate intracranial bleeding.

Neurologic examination of the infant

O p t i c N e r v e

Visual acuity can be tested in the older child by standard means .

In the toddler, an approximation can be obtained by observing him or her at play or by offering objects of varying sizes.

Neurologic examination of the infant

O p t i c N e r v e

Optokinetic nystagmus can be elicited by rotating a striped drum or by drawing a strip of cloth with black and white squares in front of the child's eyes .

The presence of optokinetic nystagmus confirms cortical vision; its absence, however, is inconclusive .

Neurologic examination of the infant

O p t i c N e r v e

The blink reflex, closure of the eyelids when an object is suddenly moved toward the eyes, is often used to determine the presence of functional vision in small infants.

Neurologic examination of the infant

O p t i c N e r v e

The macular light reflex is absent until approximately 4 months of age.

It is present in approximately one-half of healthy 5-month-old infants and should be present in all infants by 1 year of age

Neurologic examination of the infant

O p t i c N e r v e

The visual fields can be assessed in toddlers and in infants younger than 12 months of age.

The baby is placed in the mother's lap and the physician is seated in front of them, using a small toy to attract the baby's attention.

Neurologic examination of the infant

O p t i c N e r v e

An assistant standing in back of the infant brings another object into the field of vision, and the point at which the infant's eyes or head turns toward the object is noted.

Neurologic examination of the infant

Oculomotor, Trochlear, and Abducens Nerves: Extraocular Movements

The physician notes the position of the eyes at rest.

Noting the points of reflection of a flashlight assists in detecting a nonparallel alignment of the eyes.

The size of the pupils, their reactivity to light, and accommodation and convergence are noted.

Neurologic examination of the infant

Oculomotor, Trochlear, and Abducens Nerves: Extraocular Movements

A slight degree of anisocoria is not unusual, particularly in infants and small children.

Fatigue-induced anisocoria also has been noted to be transmitted as an autosomal dominant trait

Neurologic examination of the infant

Oculomotor, Trochlear, and Abducens Nerves: Extraocular Movements

Following movements are complete in all directions by approximately 4 months of age, and acoustically elicited eye movements appear at 5 months of age.

Depth perception using solely binocular cues appears by 24 months of age along with stable binocular alignment and optokinetic nystagmus.

Neurologic examination of the infant

Trigeminal Nerve

The corneal reflex tests the intactness of the ophthalmic branch of the trigeminal nerve.

A defect should be suspected when spontaneous blinking on one side is slower and less complete.

The frequency of blinking increases with maturation and decreases in toxic illnesses.

Neurologic examination of the infant

Facial Nerve

- Impaired motor function is indicated by facial asymmetry.

- The McCarthy reflex, ipsilateral blinking produced by tapping the supraorbital region, is diminished or absent in lower motor neuron facial weakness.

.

Neurologic examination of the infant

Facial Nerve

- Palpebral reflex, bilateral blinking induced by tapping the root of the nose, it can be exaggerated by upper motor neuron lesions.
- In hemiparesis or peripheral facial nerve weakness, the contraction of the platysma muscle is less vigorous on the affected side, This sign also carries Babinski's name.

Neurologic examination of the infant

Facial Nerve

An isolated weakness of the depressor of the corner of the mouth (depressor anguli oris) is relatively common in children.

It results in a failure to pull the affected side of the mouth backward and downward when crying.

- ▣ ..\..\p\all\PATIENTS\CLIPS\quiz
\Video005.3gp

DR AMR HASAN AL HASANY

- ▣ ..\..\p\all\PATIENTS\CLIPS\quiz
\Video006.3gp

DR AMR HASAN AL HASANY

Neurologic examination of the infant

Cochlear Nerve

- Hearing can be tested in the younger child by observing the child's response to a bell.
- Small infants become alert to sound; the ability to turn the eyes to the direction of the sound becomes evident by 7 to 8 weeks of age, and turning with eyes and head appears by approximately 3 to 4 months of age.

Neurologic examination of the infant

Cochlear Nerve

- Hearing is tested in older children by asking them to repeat a whispered word or number.
- For more accurate evaluation of hearing, audiometry or brainstem auditory-evoked potentials are necessary.

Neurologic examination of the infant

V e s t i b u l a r N e r v e

- Vestibular function can be assessed easily in infants or small children by holding the youngster vertically so he or she is facing the examiner, then turning the child several times in a full circle.
- Clockwise and counterclockwise rotations are performed. The direction and amplitude of the quick and slow movements of the eye are noted.

Neurologic examination of the infant

V e s t i b u l a r N e r v e

•The healthy infant demonstrates full deviation of the eyes in the direction that he or she is being rotated with the quick phase of the nystagmus backward. When rotation ceases, these directions are reversed.

Neurologic examination of the infant

Glossopharyngeal and Vagus Nerves

- The gag reflex tests the afferent and efferent portions of the vagus.
- This reflex is absent in approximately one-third of healthy individuals.
- Testing taste over the posterior part of the tongue is extremely difficult and, according to some opinions, generally not worth the effort.

Neurologic examination of the infant

S p i n a l A c c e s s o r y N e r v e

Testing the sternocleidomastoid muscle can be done readily by having the child rotate his or her head against resistance.

Neurologic examination of the infant

H y p o g l o s s a l N e r v e

- The position of the tongue at rest should be noted with the mouth open.

- The tongue deviates toward the paretic side.

- Fasciculations are seen as small depressions that appear and disappear quickly at irregular intervals.

Neurologic examination of the infant

H y p o g l o s s a l N e r v e

• They are most readily distinguished on the underside of the tongue.

• Their presence cannot be determined with any reliability if the youngster is crying.

Neurologic examination of the infant

M o t o r s y s t e m e x a m i n a t i o n :

• Similarly, the walking and running gaits can be seen by playing with the youngster and asking him or her to retrieve a ball and run outside of the examining room .

• In the course of such an informal examination, sufficient information can be obtained so that the formal testing of muscle strength is only confirmatory .

Neurologic examination of the infant

In toddlers or infants, inequalities of tone have been found to provide more information than assessment of muscle strength or reflexes.

A sensitive test for weakness of the upper extremities is the **pronator sign**, in which the hand on the hypotonic side hyperpronates to palm outward as the arms are raised over the head. Additionally, the elbow may flex .

DR AMR HASAN AL HASANY



Neurologic examination of the infant

In the lower extremities, weakness of the flexors of the knee can readily be demonstrated by having the child lie prone and asking the child to maintain his or her legs in flexion at right angles at the knee .

An unsustained ankle clonus is common in the healthy neonate .

Neurologic examination of the infant

C o o r d i n a t i o n

Coordination can be tested by applying specific tests for cerebellar function, such as having the youngster reach for and manipulate toys.

The ability to perform rapidly alternating movements can be assessed by having the child repeatedly pat the examiner's hand, or by having the child perform rapid pronation and supination of the hands.

Neurologic examination of the infant

C o o r d i n a t i o n

The heel-to-shin test is not an easy task for many youngsters to comprehend, and performance must be interpreted with regard to the child's age and level of intelligence.

Neurologic examination of the infant

Sensory Examination

- ▣ A proper sensory examination is difficult at any age, and almost impossible in an infant or toddler.
- ▣ In infants or toddlers, abnormalities in skin temperature or in the amount of perspiration indicate the level of sensory deficit.

Neurologic examination of the infant

Sensory Examination

- ▣ The ulnar surface of the examiner's hand has been found to be the most sensitive, and by moving the hand slowly up the child's body, one can verify changes that one marks on the skin and rechecks on repeat testing.
- ▣ Object discrimination can be determined in the healthy school-aged child by the use of coin, or small, familiar items such as paperclips or rubber bands.

Neurologic examination of the infant

Reflexes

A positive response to Babinski sign is seen normally in the majority of 1-year-old children and in many up to 2 1/2 years of age.

In the sequential examination of infants conducted by Gingold and her group, the plantar response becomes consistently flexor between 4 and 6 months of age

Neurologic examination of the infant

Reflexes

Several beats of ankle clonus can be demonstrated in some healthy newborns and in some tense older children.

A sustained ankle clonus is abnormal at any age and suggests a lesion of the pyramidal tract.

Neurologic examination of the infant

Reflexes

Children with developmental disabilities, such as minimal brain dysfunction and attention-deficit disorders, are often found to have soft signs on neurologic examination

Neurologic examination of the infant

These represent persistence of findings considered normal at a younger age. Of the various tests designed to elicit soft signs:

1. Tandem walking: is performed successfully by 90% of 5-year-old children; 90% of 7-year-old children also can hop in one place.

Neurologic examination of the infant

1. H o p p i n g o n o n e f o o t .
2. Ability of the child to suppress overflow movements when asked to repetitively touch the index finger to the thumb.

Neurologic examination of the infant

A positive response to Babinski sign is seen normally in the majority of 1-year-old children and in many up to 2 1/2 years of age .

In the sequential examination of infants conducted by Gingold and her group, the plantar response becomes consistently flexor between 4 and 6 months of age

- ▣ [exam video\05 Func int-MS-Tone.mpg](#)

DR AMR HASAN AL HASANY

- ▣ [exam video\07 Func_int-DTRfx-Cerfunc.mpg](#)

DR AMR HASAN AL HASANY

▣ [exam video\08 Func int-Sens-Gait-MenS.mpg](#)

DR AMR HASAN AL HASANY





- ▣ exam video\09
Musculoskeletal Apparatus.mpg

DR AMR HASAN AL HASANY

Thank you

DR AMR HASAN AL HASANY



	28 weeks	32 weeks	34 weeks	40 weeks	Red flags
Mental status	Needs gentle rocking to awaken	Opens eyes spontaneously; sleep-wake cycles apparent		At 36 wks ↑ alertness, cries when awake	Irritable or lethargic infant
Cranial nerves Pupils	Blinks to light	Consistent pupillary reflex	Fix and follow		
Hearing	Flashes, no orientation to sound			Head + eyes turn to sound	-No response to auditory stimulus
Suck + swallow	Weak suck, no synchrony with swallow	Stronger suck, better synchrony with swallow		Coordinated suck + swallow at 37 wks	-“Chomp suck” - clamps down on pacifier but no suck (bulbar dysfunction)
Motor	 Minimally flexed	 Flexed hips and knees	 ↑ Flexion at hips + knees	 Flexed in all extremities	-Hypotonia -Hypertonia -28 wk infant with jerky movements -Full-term infant with writhing movements
Reflexes Moro	Weak incomplete, hand opening	Complete extension + abduction		Full Moro (with arm flexion)	-Asymmetry
ATNR				ATNR appears at 31 wks	-If obligatory or sustained, suggests pyramidal or extrapyramidal motor abnormal
Palmar grasp	Present but weak		Grasp stronger	Strong grasp, able to be lifted out of bed	-Fixed obligate grasp (suggests B hemispheric dysfunction)