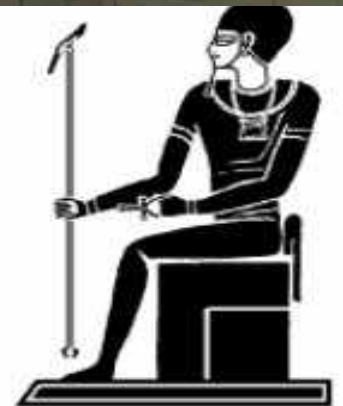



Basic Clinical assessment of Ataxia



Amr Hasan, M.D.
Associate Professor of Neurology
Cairo University



DR

History Taking

- Intention kinetic tremors
- Unsteadiness of gait
- Stacatto speech
- Nystagmus

History Taking

- The condition was also associated with AIMs that are absent during rest, occur on action, increase on approaching the target.
- The condition is also associated with unsteadiness of gait with deviation to either side.
- The condition is also associated with difficulty in articulation despite good communication.

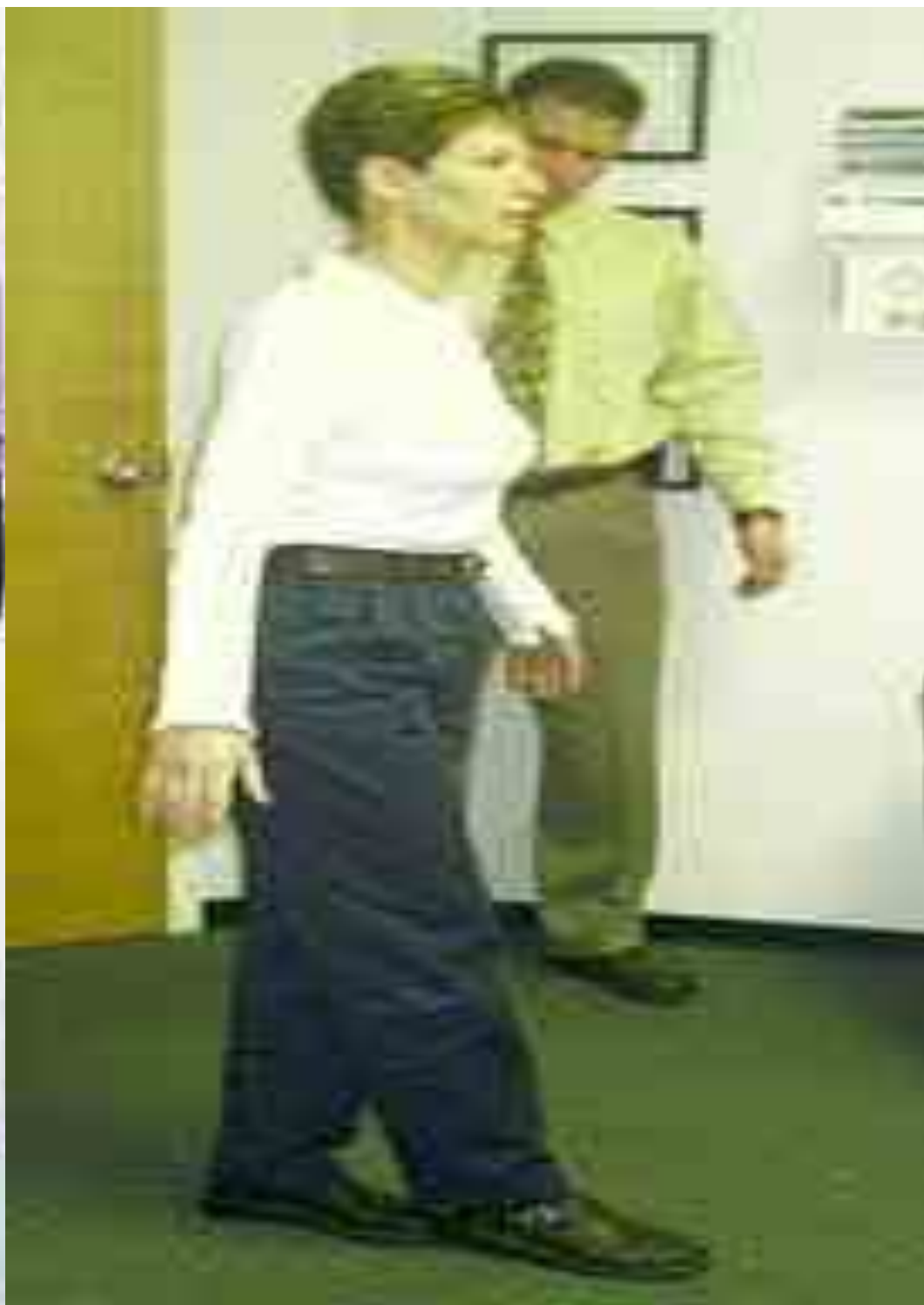Examination of Coordination

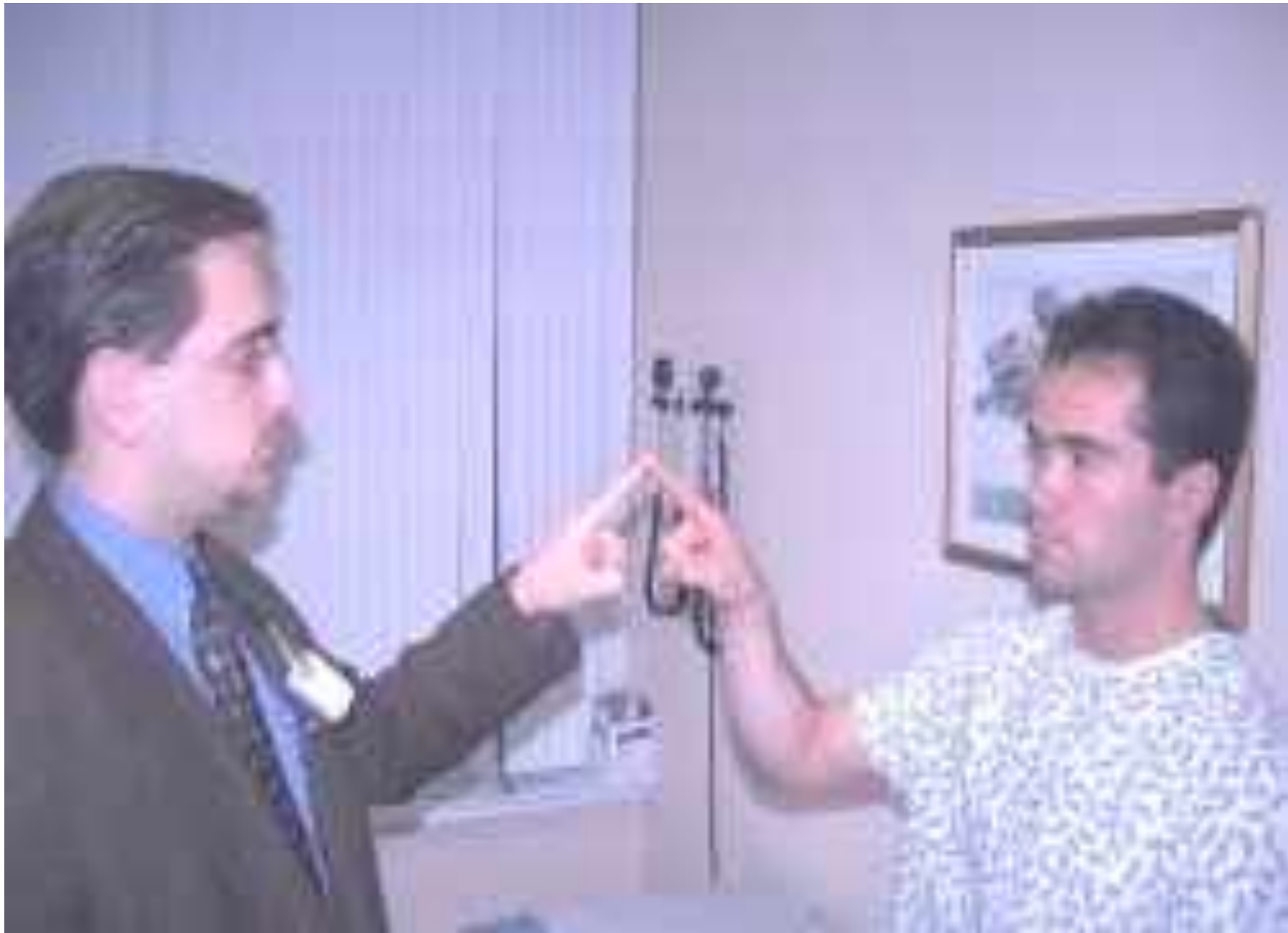Upper limb

- Finger to nose, to finger, to doctor finger. Assess decomposition, intention tremors and dysmetria.
- Dysdiadokokinesia
- Rebound phenomena
- Buttoning and unbuttoning

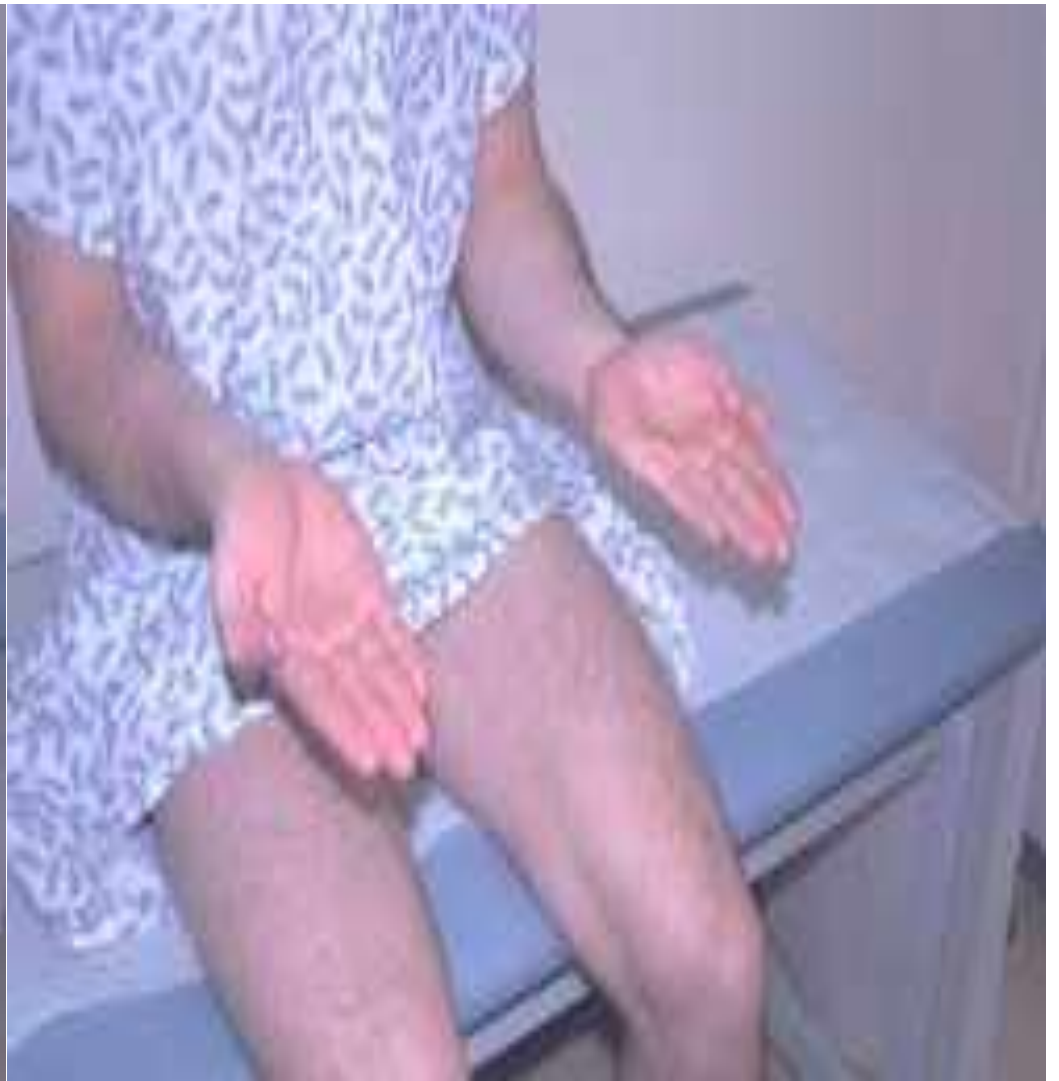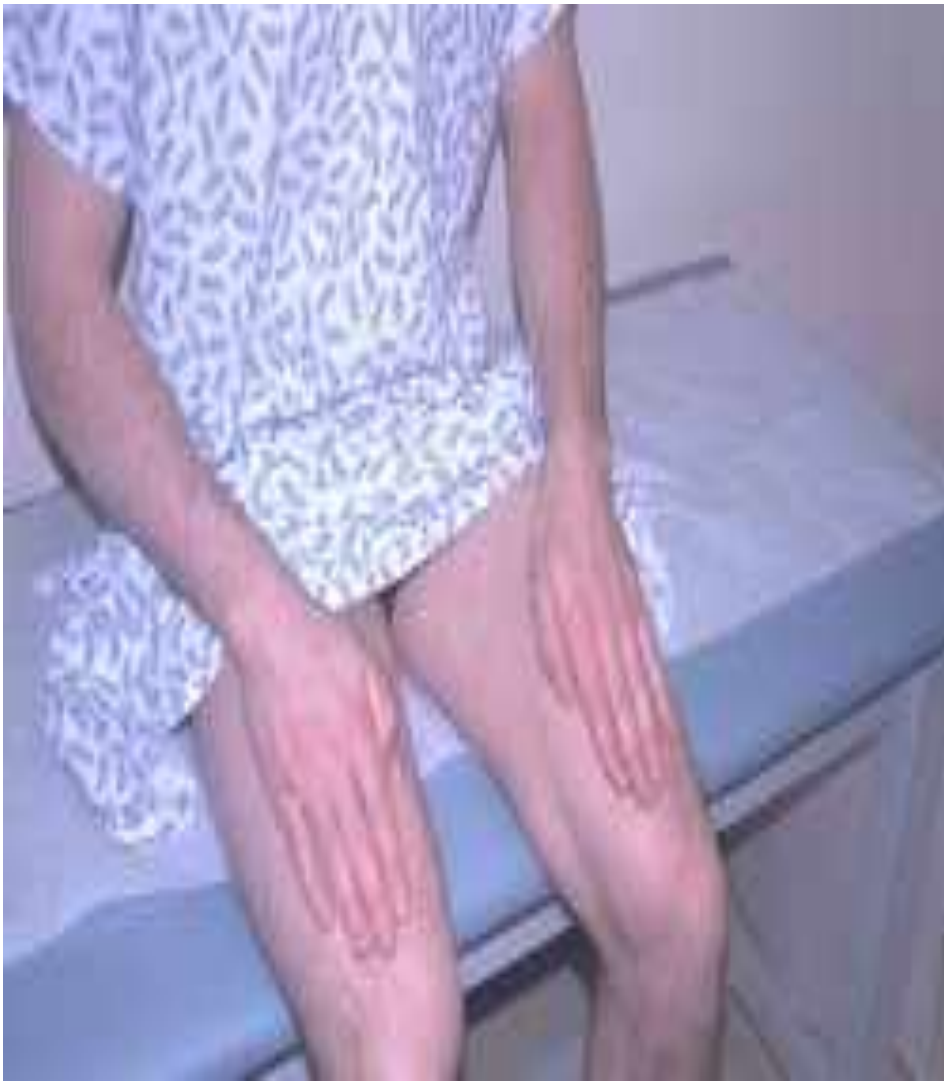Lower limb

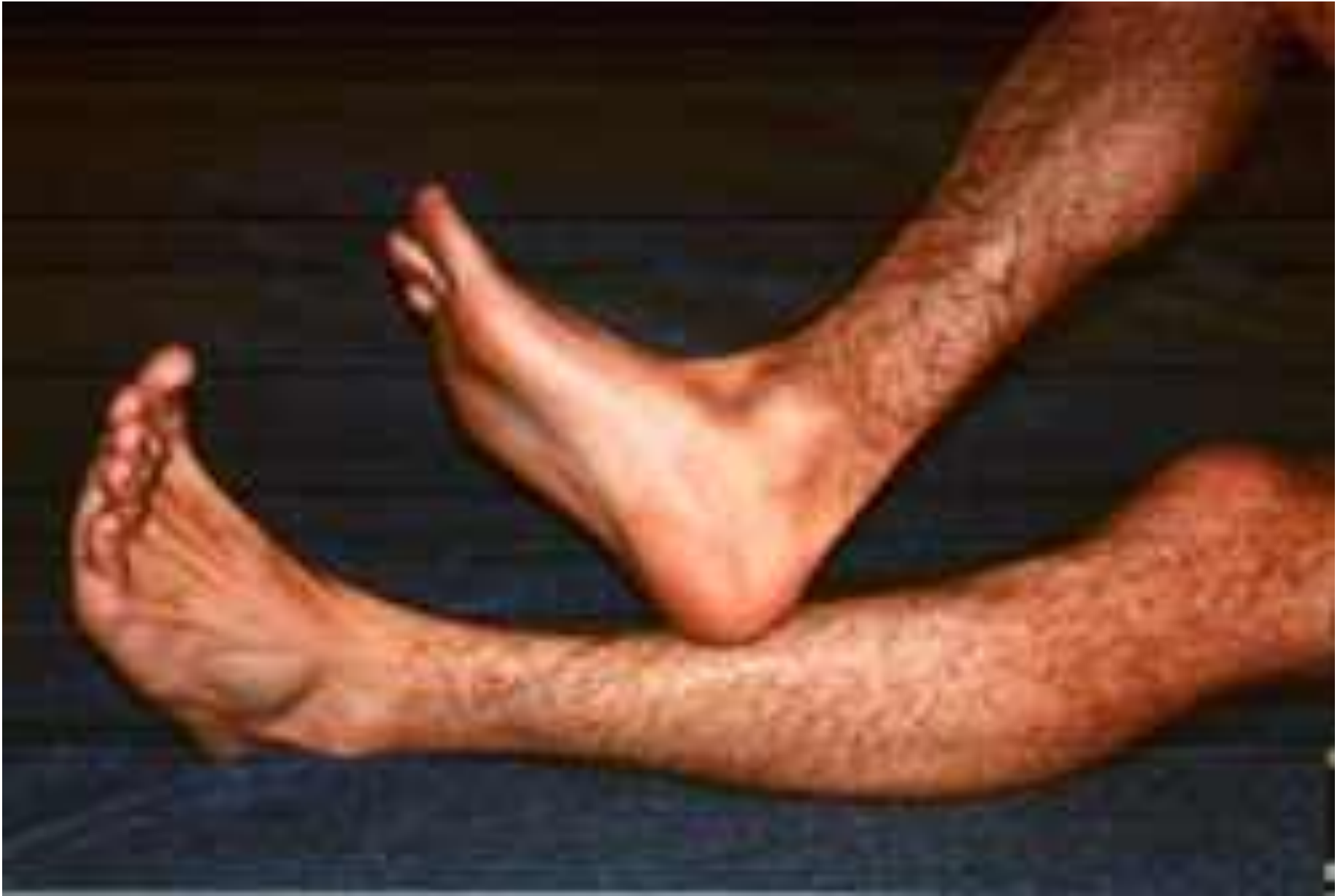- Heel to knee test
- Walking straight
- Romberg test

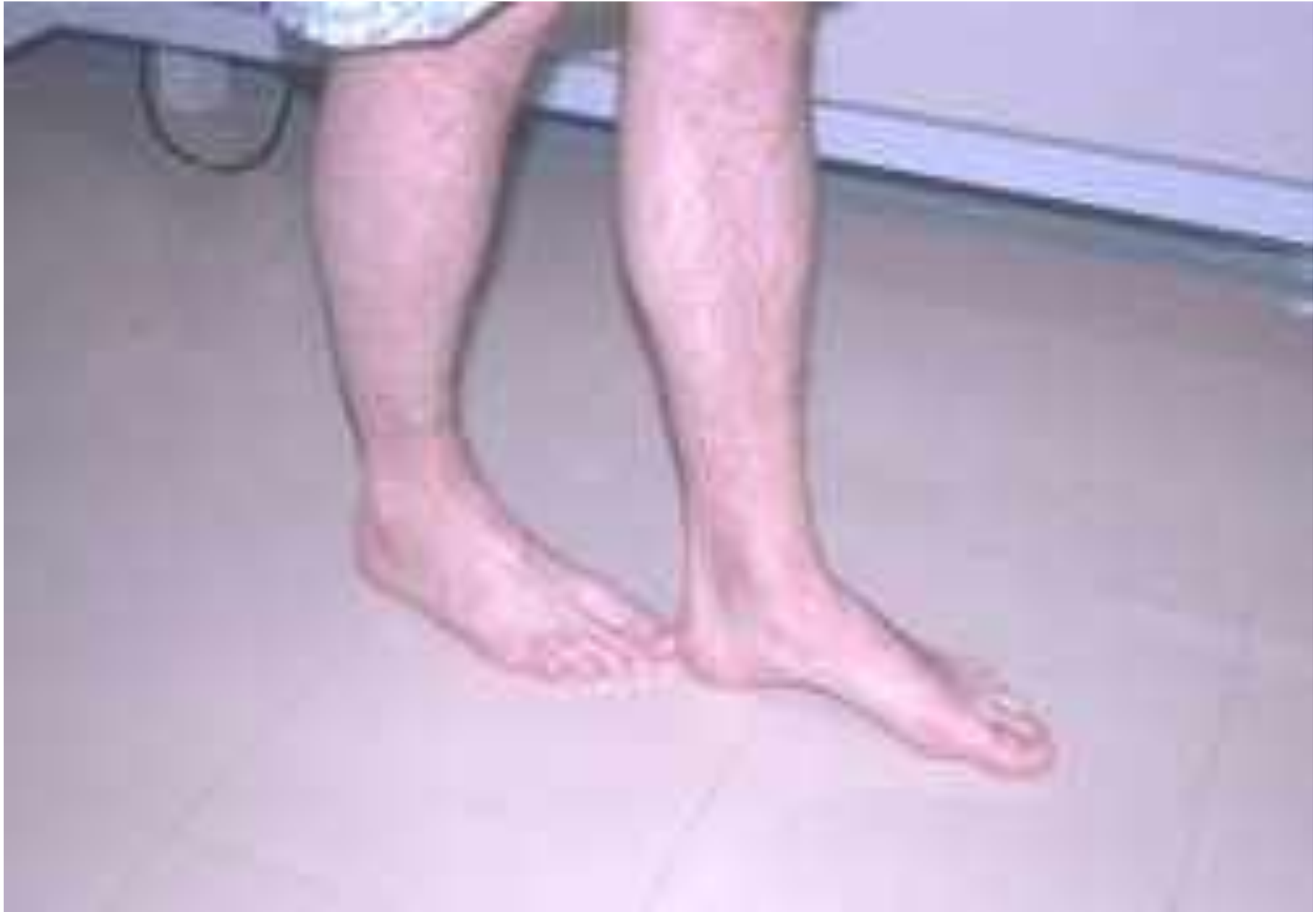


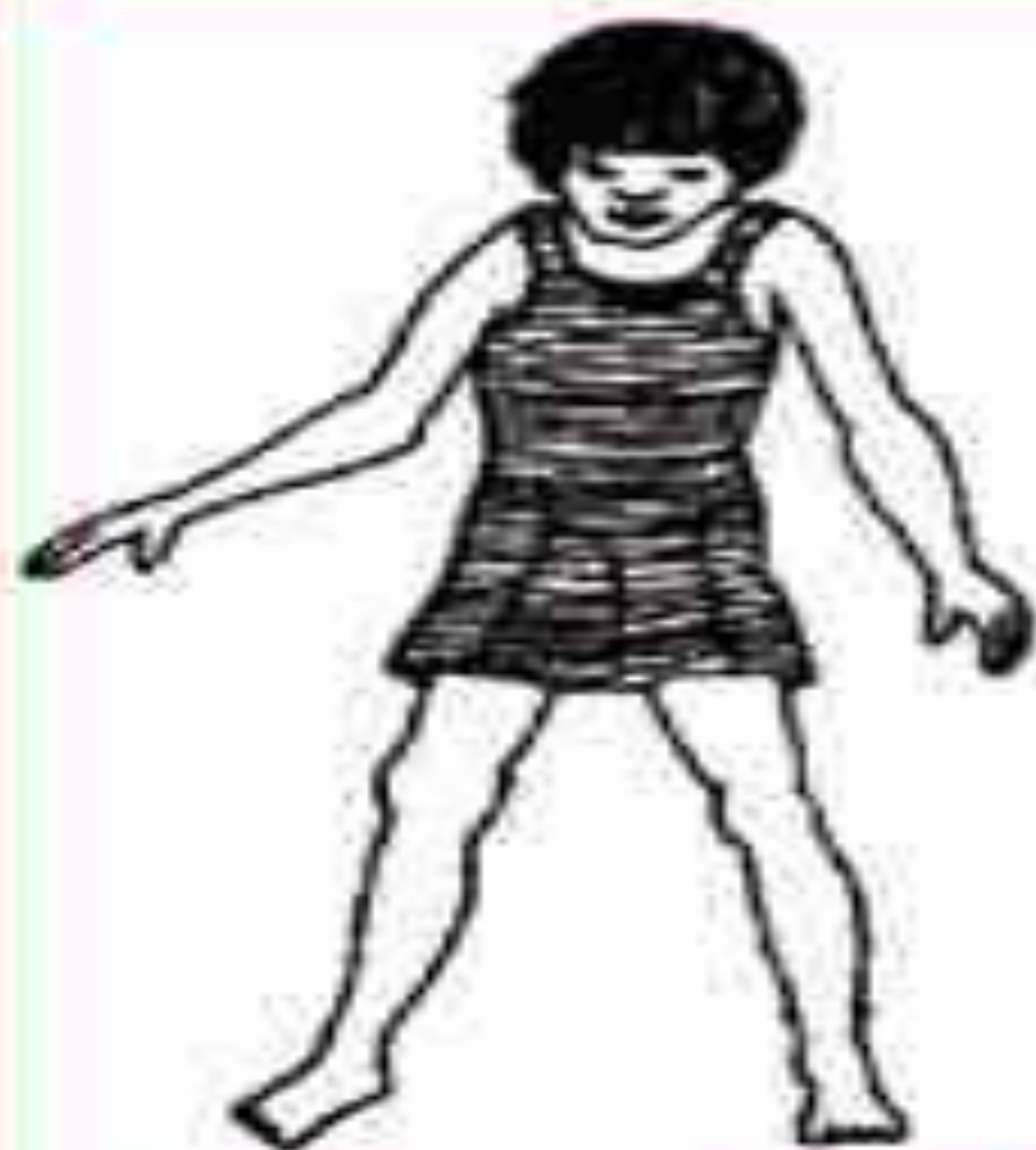
DR AMR HASAN AL HASANY

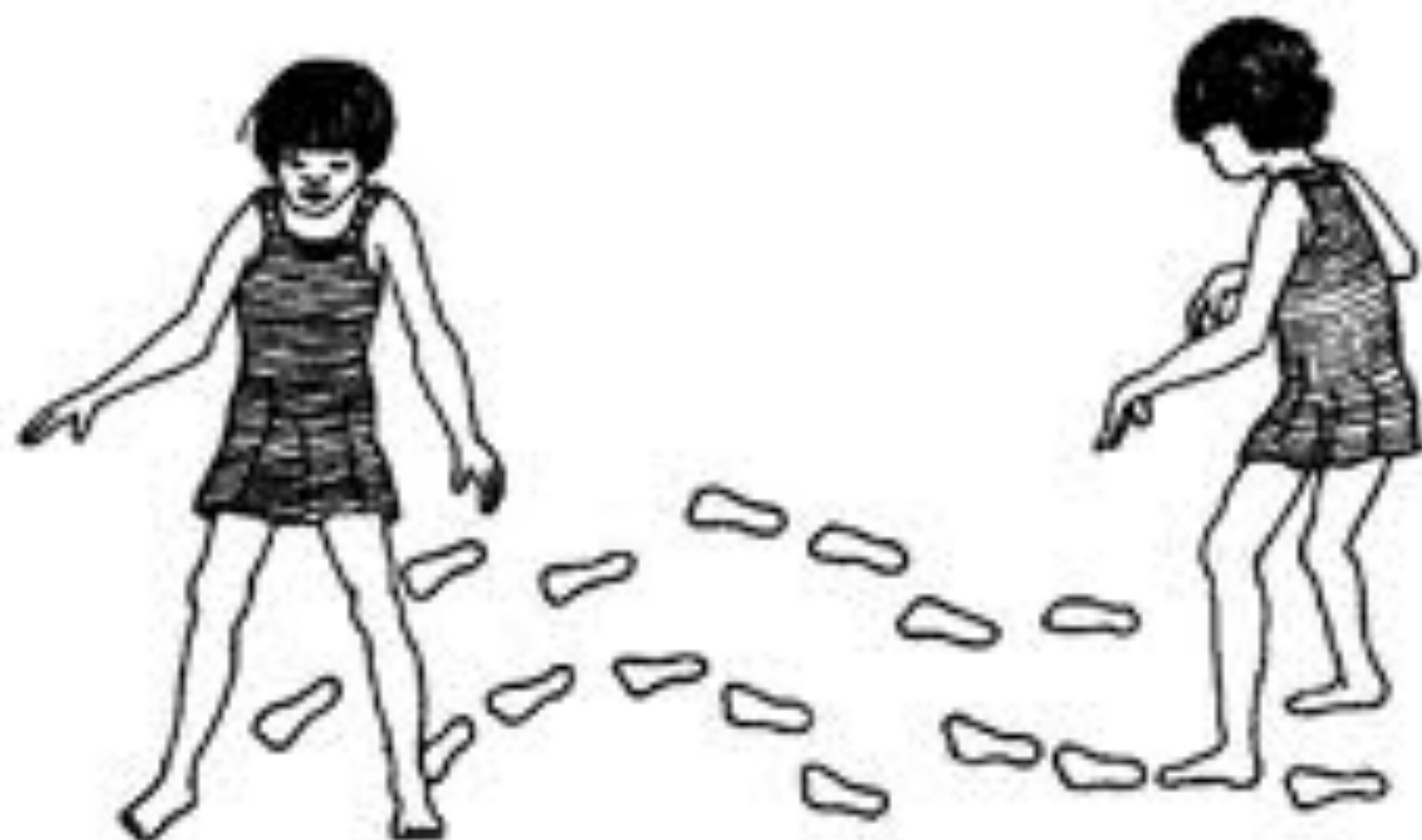











Ataxia de Friedreich





To keep her balance the child with ataxia walks bent forward with feet wide apart. She takes irregular steps, like a sailor on a rough sea or someone who is drunk.











THANK YOU